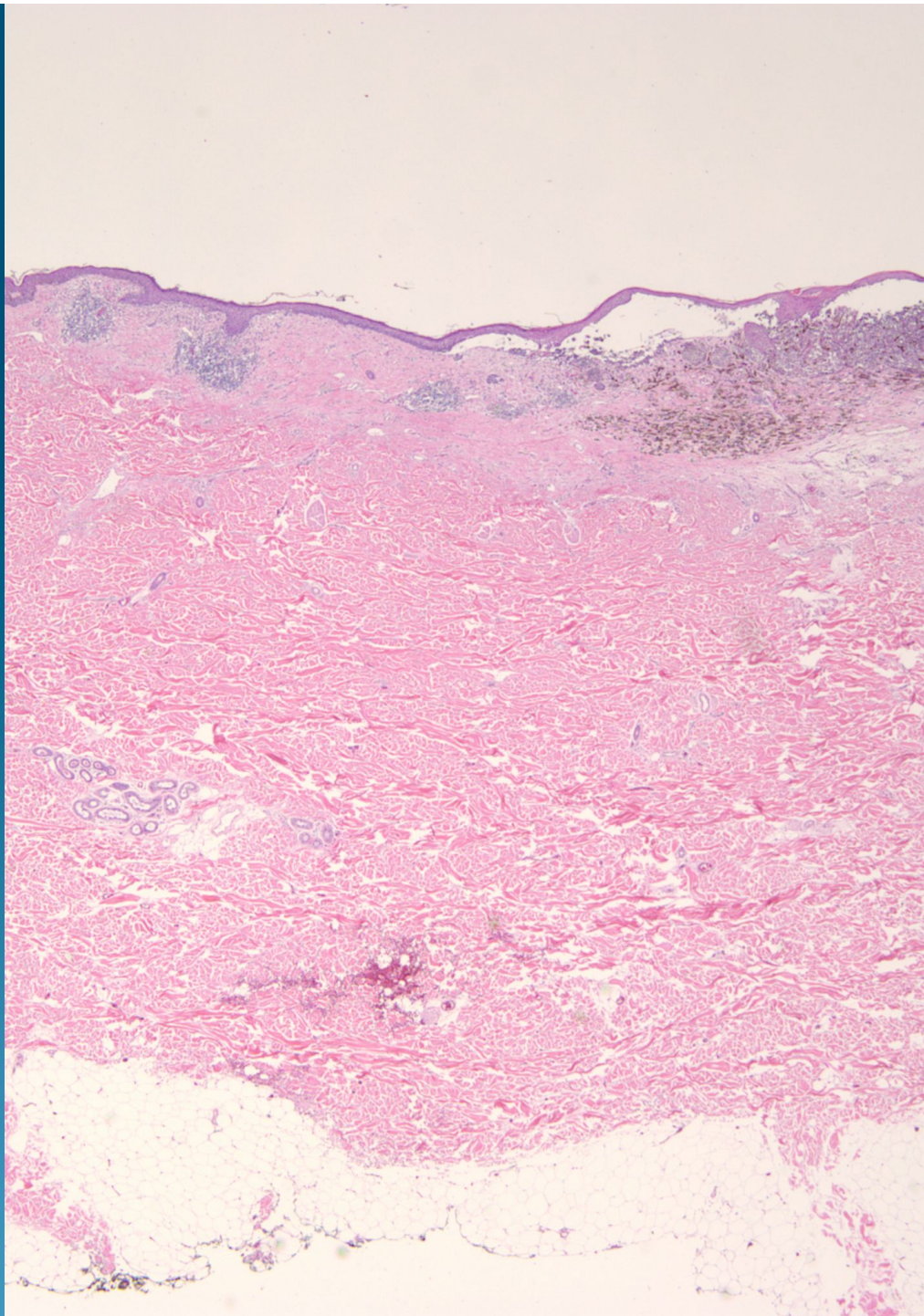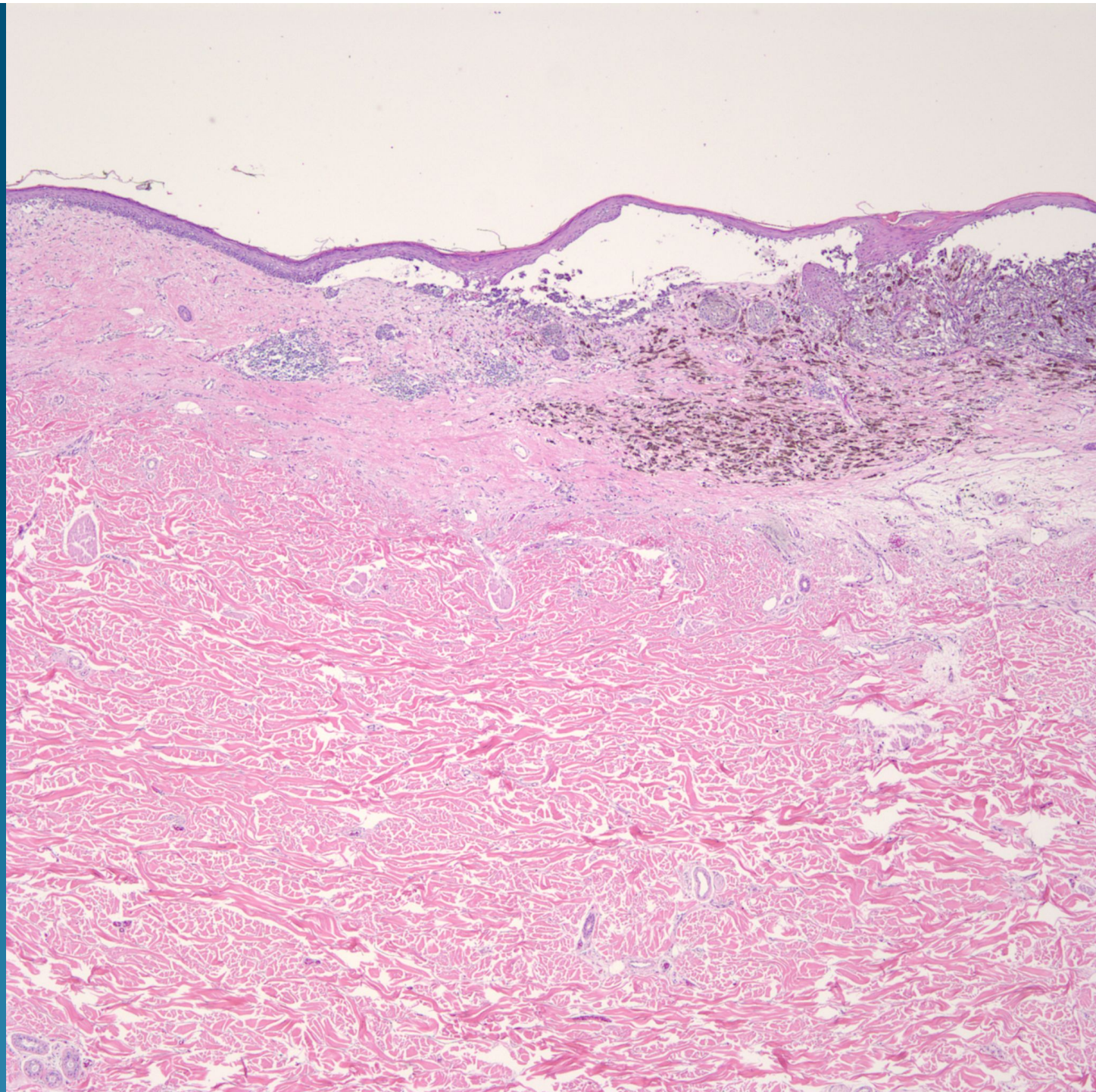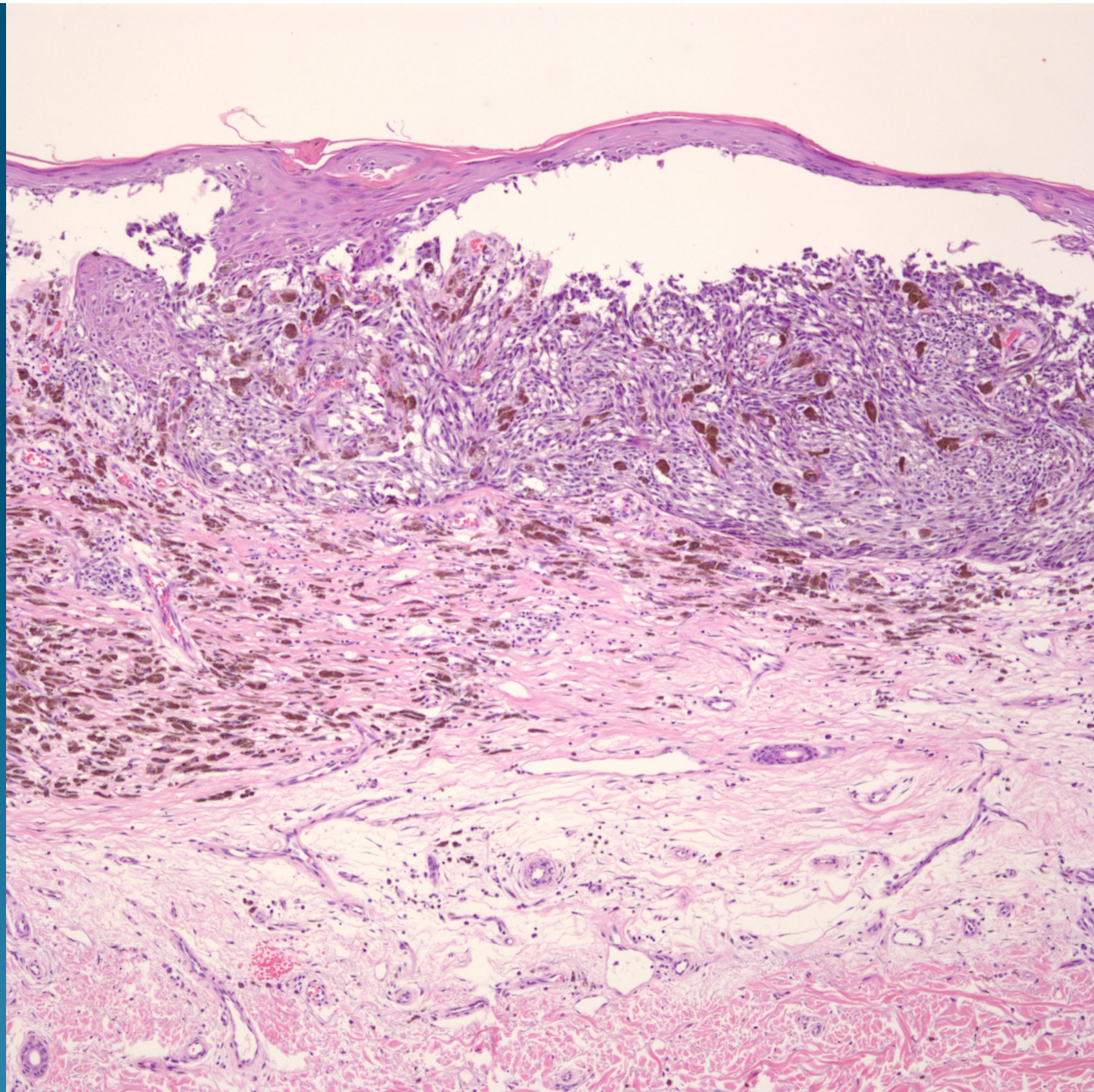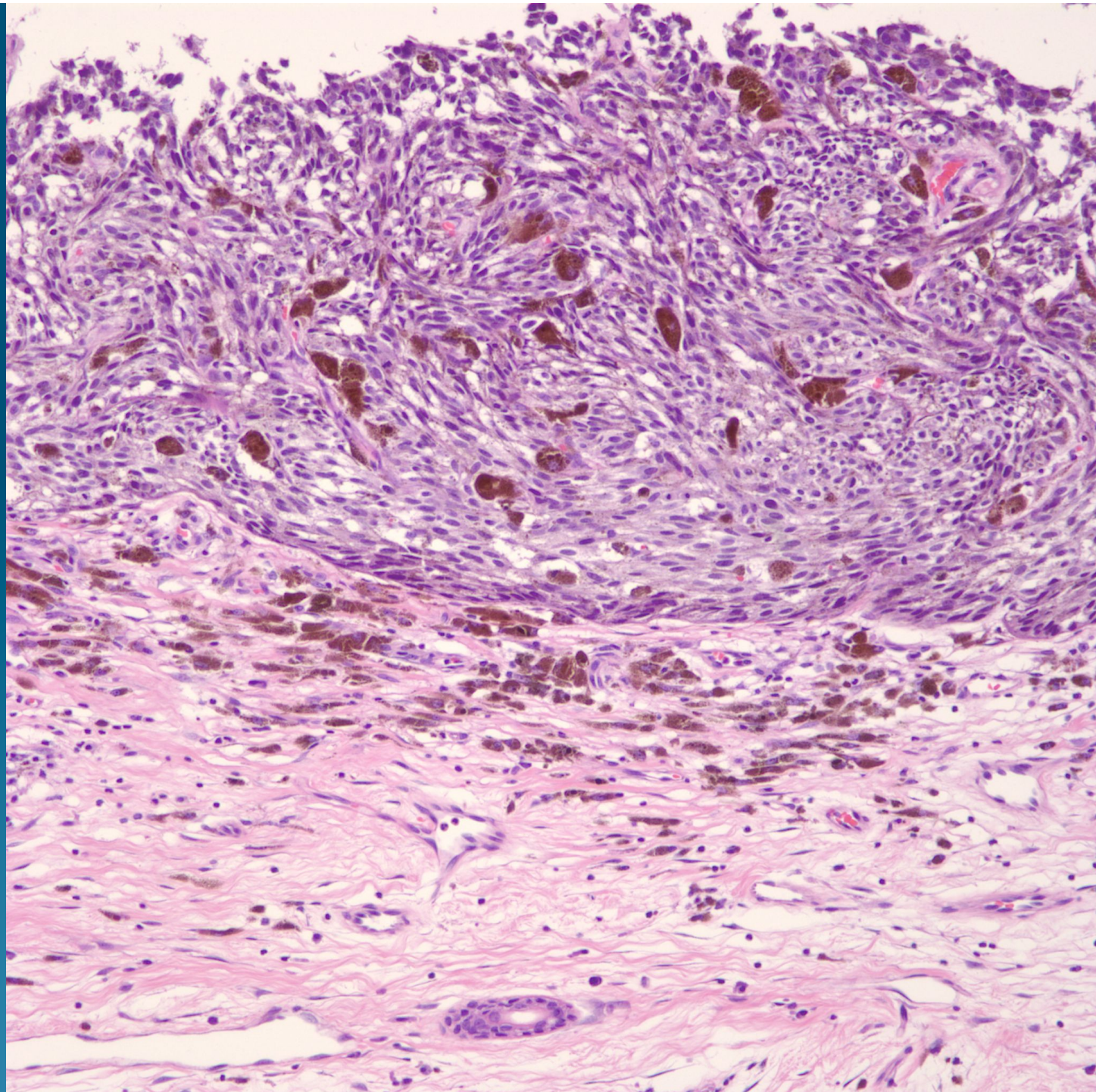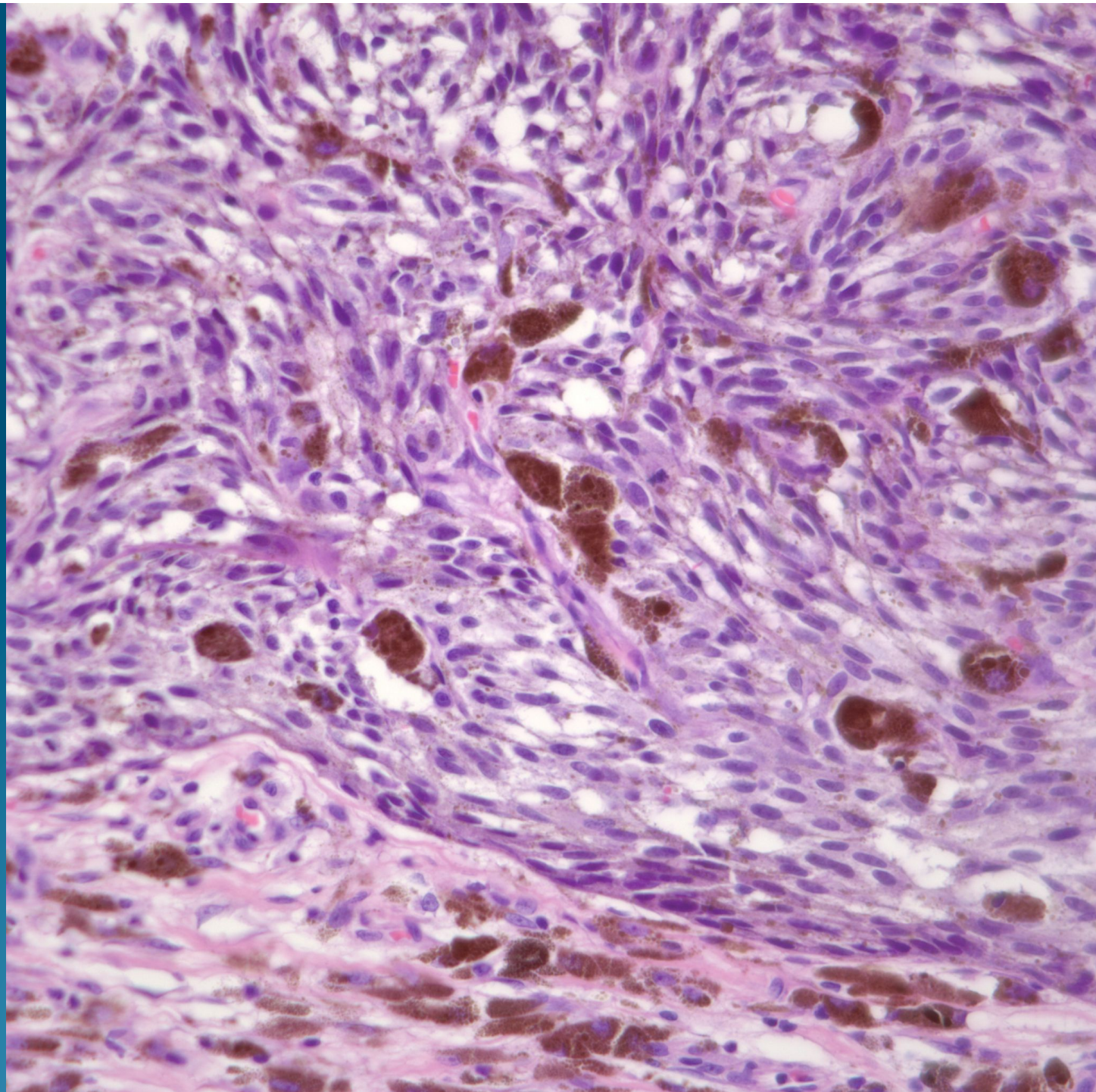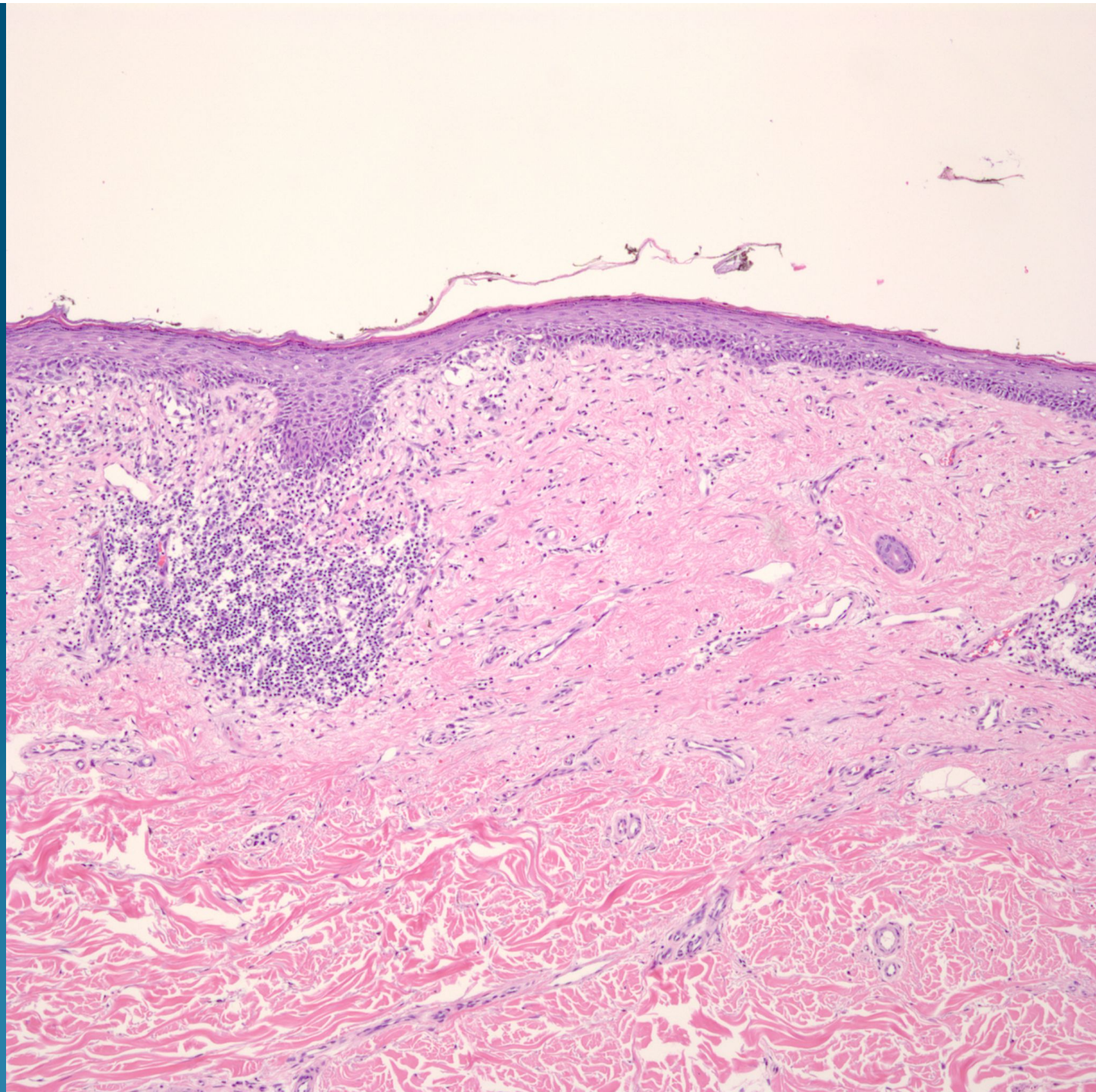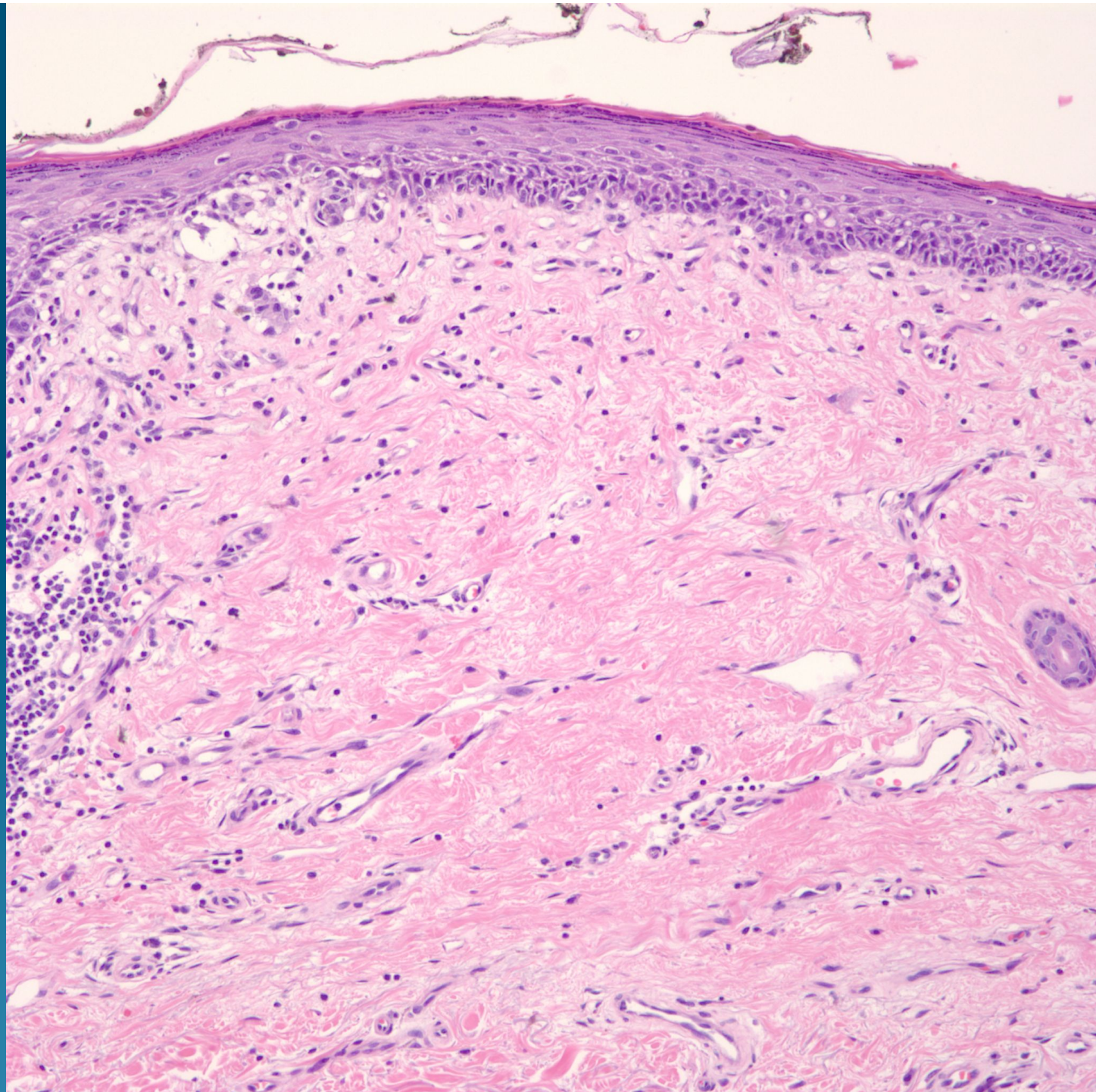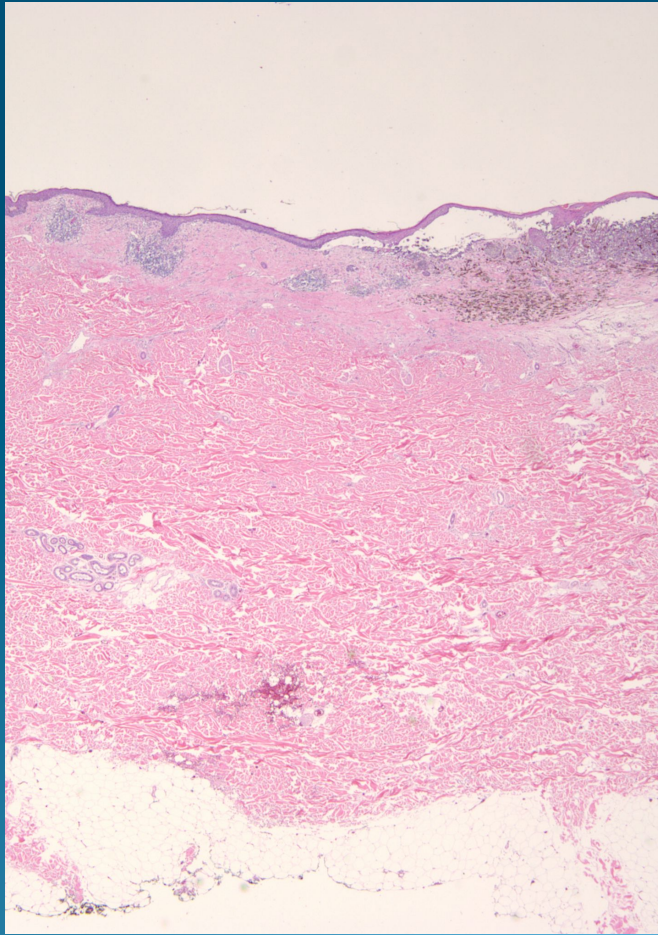


Malignant Melanoma with Regression

Pearls



- Regression characterized by fibroplasia and scar-like changes with telangiectasia, flattening of the rete ridges and/or epidermal atrophy, melanophages, drop out of melanocytes
- Note in this case regressed areas arising adjacent to melanoma-but atypical junctional melanocytes still present (latter is inconstant finding)